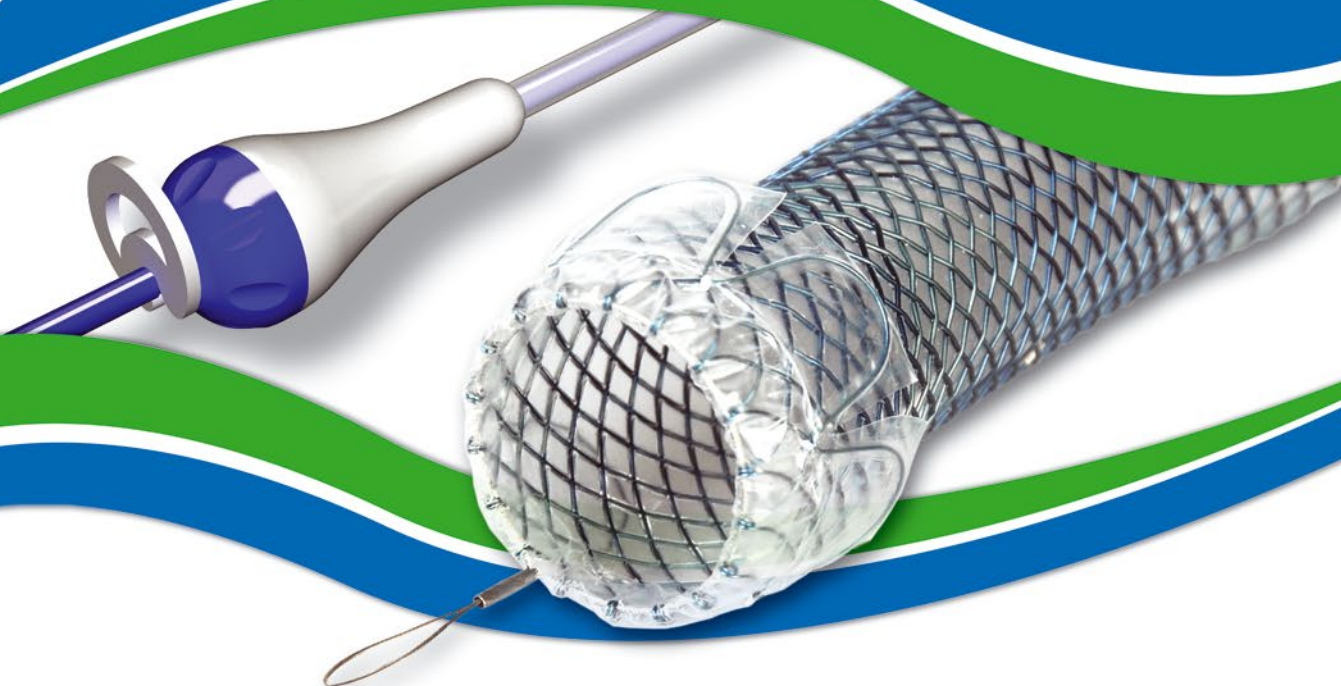



ELLA-HV anti-migration stent demonstrates superior performance for cancers of the gastroesophageal junction

Mercer J, Najran P, Edwards DW, Borg P, Mullan D, Bell J, Laasch H-U
BSIR Annual meeting, Birmingham, 1st to 3rd Nov 2017

...Results: **79 stent** procedures were identified. There was **100% success** in placing the stent across the GOJ and no reports of failure at 24 hours. Median follow up was 75 days (7-452). **4/79 (5.1%)** stents migrated distally (95% CI: 1.6-12.7%), compared with **109/615 (17.7%)** stent in ROST 2 registry (95% CI: 14.7-20.7%). Reduced distal migration was observed (5% significance level, $p = 0.004$), with a corresponding **reduction in migration rate of 71.4%**. ... The Ella HV stent confers a statistically significant reduction in distal migration compared with stent types recorded in the national registry, reducing the need for re-intervention with associated risks and cost.

Oesophageal stents with anti-migration design: Getting a grip on stent displacement

Philbin CA, Stivaros SM, Mullan D et al.
BSIR Annual meeting, Manchester, 13th to 15th Nov 2013

...All Ella-HV antireflux stents placed across the cardia over a 6 year period in a supraregional cancer centre were reviewed ... Outcome data were compared with national figures from the registry (Registry of Oesophageal Stenting - ROST) ... 32 stents procedures were included ... **6.3% (2/32) stents migrated** (95% CI 0-21.2%) compared to **17.7% (109/615) in ROST 2** ($p=0.046$). Two stents remained in place, where a different stent had migrated previously ... In this small study the anti-migration design of the **Ella-HV stent reduced the displacement rate by 60%** compared to the national average...

A comparison of oesophageal self-expanding metal stents and their complications

C. Davidson, C. Rutherford, J. Allan, G. Simpson, J. Gray. (2016)
Royal Alexandra Hospital, GGC NHS Trust, Glasgow, UK.
International Journal of Surgery. 36. S88. 10.1016/j.ijvs.2016.08.294.

...A total of **98 SEMS** were inserted, of which the most common were **XS Ella** and **Niti S**, with **54** and **22** inserted respectively. The remaining stent types were either not documented (19), metal (1), Ultra flex (1) or Boston Scientific Polyflex (1). Complications included blockage (total 6/98; **XS Ella 2/54**; Niti S 2/22) migration (total 15/98; **XS Ella 0/54**; Niti S 4/22) perforation (total 4/98; **XS Ella 0/54**; Niti S 2/22) and pain (total 7/98; **XS Ella 2/54**; Niti S 2/22)...

Fully covered stents versus partially covered stents for palliative treatment of esophageal cancer: Is there a difference?

J.O. Alonso Lárraga, D.Y. Flores Carmona, A. Hernández Guerrero, M.E. Ramírez Solís, J.G. de la Mora Levy y J.C. Sánchez del Monte
Departamento de Endoscopia Gastrointestinal, Instituto Nacional de Cancerología, Ciudad de México, México Recibido el 30 de septiembre de 2016; aceptado el 5 de julio de 2017

...A retrospective study was conducted on patients with inoperable esophageal cancer treated with self-expandable metallic stents. The 2 groups formed were: **group A**, which consisted of patients with a **fully covered** self-expandable stent (**SX-ELLA®**), and group B, which was made up of patients with a **partially covered** self-expandable stent (Ultraflex®). ... **Group A - Technical**

success was achieved in 100% (n = 21) of the cases and clinical success in 90.4% (n = 19). Group B - Technical success was achieved in 100% (n = 29) of the cases and clinical success in 89.6% (n = 26). Complications were similar in both groups (33.3 vs. 51.7%) and included beside others early migration (3/21 vs. 3/26), late migration (1/21 vs. 2/26), obstruction by tumour (0/21 vs. 5/26)...

Insertion of Removable Self-Expanding Metal Stents as a Treatment for Postoperative Leaks and Perforations of the Esophagus and Stomach

Inbar R, Santo E, Subch AE et al.

Israel Medical Association Journal; 2011; 13: 230–233

...Between June 2009 and February 2010 ... the **SX-ELLA esophageal stent** was inserted in five patients ... the indications for stent insertion were postoperative leak in four patients and postoperative esophagopleural fistula in one patient. Three of the patients had a leak at the gastroesophageal junction following laparoscopic sleeve gastrectomy ... There were **no documented complaints in any of the patients regarding dysphagia or chest pain** ... Stents were removed electively after 6 to 7 weeks...

Combined use of fluoroscopically guided fibrin sealant and removable metallic stent for oesophageal leak/perforations

Swift AJ, Chiu K, Razack A.

European Society of Radiology, ECR Congress 2010, Poster No.: C-3312

...**Four cases of oesophageal leaks/perforations** treated by injection of fibrin-glue sealant and covered stent ... a removable covered metallic stent SX-ELLA HV oesophageal stent ... following fibrin-glue injection, 3 of 4 cases showed complete occlusion of track ... one patient who had a > 2cm neck to the leak required two treatments using the same method before the leak was successfully treated ... **all four patients were re-commenced on oral feeds and made a good recovery** and the stents were removed between 6 and 8 weeks...

Safety and efficacy of self-expanding removable metal esophageal stents during neoadjuvant chemotherapy for resectable esophageal cancer

Pellen M. G. C., Sabri S., Razack A. et al.

Diseases of Esophagus; 2012; 25, 48–53


...Sixteen patients underwent esophageal stenting during neoadjuvant therapy ... tumors were located in the lower one third of the esophagus ... **Stent migration was anticipated in response to tumor regression**. Patients were counseled that this was a potential outcome and slippages were readily retrieved endoscopically or at operation ... **Stents migrated during neoadjuvant therapy in 7/16 (43.8%) patients** ... Outcomes in our series suggest that **SERMS could be considered a safe and feasible alternative method of maintaining nutritional supplementation during neoadjuvant chemotherapy for stenosing esophageal cancers**...

Stent-in-Stent Technique for Removal of Embedded Esophageal Self-Expanding Metal Stents

Hirdes MMC, Siersema PD, Houben MHMG et al.

American Journal of Gastroenterology (AJG) 2011; 106: 286–293

...Removal of embedded, partially covered SEMSs by induction of pressure necrosis using the stent-in-stent technique ... partially covered SEMSs were inserted for malignant (n = 3) or benign (n = 16) conditions and were left in situ for a median of 42 days (14 – 189) ... When SEMSs were found to be embedded, a fully covered self-expanding plastic stent (SEPS) or fully covered SEMS (SX-Ella) ... was placed inside the partially uncovered SEMS. Subsequent removal of both stents was planned after a period of 10 – 14 days...



Self-Expandable Stents in the Gastrointestinal Tract

KOZAREK, Richard, Todd BARON and Ho-Young SONG. Self-expandable stents in the gastrointestinal tract. New York: Springer, 2012, p. cm. ISBN 978-146-1437-451.

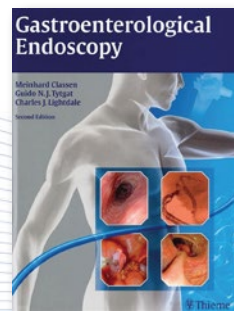
In this textbook the HV Stent and HV Stent Plus* are mentioned for their flexibility, removability and especially for their antimigration features. Refer to pages 55 and 61–63. Also special features of the delivery system are mentioned at page 67 and 68.

...The Ella-HV stent (ELLA-CS) has forward facing wings around the circumference of the proximal stent end, resulting in a collar, which anchors it against the stenosis ... Better conformability of a braided esophageal stent (HV stent) compared to a laser-cut stent...

Gastroenterological Endoscopy

CLASSEN, Meinhard, G TYTGAT and Charles J LIGHTDALE. Gastroenterological endoscopy. 2nd ed. New York: Thieme, c2010, xxvii, 824 p. ISBN 31-312-5852-7.

This renowned textbook is giving a list of standard nitinol esophageal stents on the page 35. The HV stent is listed as well as other products of the ELLA-CS company.



*In above mentioned publications various names of the HV Stent Plus are used of which some represent former design of the stent (HV Stent) and some are just incomplete designation (SX-ELLA esophageal stent) of the ELLA CS most popular multi-purpose esophageal stent. The current version - HV Stent Plus - retains all valuable qualities of former design adding the advantage of durable silicone covering.